

Autoimmune markers and vascular immune deposits in Finkelstein-Seidlmayer vasculitis: Systematic literature review

Gabriel Bronz^{a,1}, Jvan Gianini^{b,c,1}, Alberto G. Passi^c, Mattia Rizzi^{a,d}, Marcel M. Bergmann^{d,e,f}, Gregorio P. Milani^{g,h}, Sebastiano A.G. Lava^{i,j}, Mario G. Bianchetti^{b,d}, Benedetta Terziroli Beretta-Piccoli^{d,k,l,*}, Federica Vanoni^{a,d}

^a Pediatric Institute of Southern Switzerland, Ente Ospedaliero Cantonale, Bellinzona, Switzerland

^b Family Medicine, Faculty of Biomedical Sciences, Università Della Svizzera Italiana, Lugano, Switzerland

^c Department of Medicine and Surgery, University of Insubria, Varese, Italy

^d Faculty of Biomedical Sciences, Università Della Svizzera Italiana, Lugano, Switzerland

^e Centro Pediatrico Del Mendrisiotto, Mendrisio, Switzerland

^f Pediatric Allergy Unit, Department of Woman, Child and Adolescent, University Hospitals of Geneva, Geneva, Switzerland

^g Pediatric Unit, Fondazione IRCCS Ca' Granda Ospedale Maggiore Policlinico, Milan, Italy

^h Department of Clinical Sciences and Community Health, Università Degli Studi di Milano, Milan, Italy

ⁱ Pediatric Cardiology Unit, Department of Pediatrics, Centre Hospitalier Universitaire Vaudois and University of Lausanne, Lausanne, Switzerland

^j Heart Failure and Transplantation, Department of Pediatric Cardiology, Great Ormond Street Hospital, London, United Kingdom

^k Epatocentro Ticino, Lugano, Switzerland

^l Faculty of Life Sciences & Medicine, King's College London, King's College Hospital, London, United Kingdom

ARTICLE INFO

Handling Editor: M.E. Gershwin

Keywords:

Finkelstein-seidlmayer vasculitis
Acute hemorrhagic edema Bibliographic database
Rheumatoid factor
Anti-nuclear antibodies
Immunoglobulin A

ABSTRACT

Finkelstein-Seidlmayer vasculitis, also called acute hemorrhagic edema of young children or infantile immunoglobulin A vasculitis, is habitually a benign skin-limited small vessel leukocytoclastic vasculitis that mainly affects infants 24 months or less of age. Since this disease is commonly triggered by an infection, an immune-mediated origin has been postulated. To better appreciate the possible underlying immune mechanism of this vasculitis, we addressed circulating autoimmune markers and vascular immune deposits in patients contained in the Acute Hemorrhagic Edema Bibliographic Database, which incorporates all original reports on Finkelstein-Seidlmayer vasculitis. A test for at least one circulating autoimmune marker or a vascular immune deposit was performed in 243 cases. Subunits of complement system C4 resulted pathologically reduced in 4.7% and C3 in 1.4%, rheumatoid factor was detected in 6.1%, and antinuclear antibodies in 1.9% of cases. Antineutrophil cytoplasmic antibodies were never demonstrated. Immunofluorescence studies were performed on 125 skin biopsy specimens and resulted positive for complement subunits in 46%, fibrinogen in 45%, immunoglobulin A in 25%, immunoglobulin M in 24%, immunoglobulin G in 13%, and immunoglobulin E in 4.2% of cases. Infants testing positive for vascular immunoglobulin A deposits did not present a higher prevalence of systemic involvement or recurrences, nor a longer disease duration. In conclusion, we detected a very low prevalence of circulating autoimmune marker positivity in Finkelstein-Seidlmayer patients. Available immunofluorescence data support the notion that immune factors play a relevant role in this vasculitis. Furthermore, vascular immunoglobulin A deposits seem not to play a crucial role in this disease.

1. Introduction

Finkelstein-Seidlmayer vasculitis, also called cockade purpura with edema, acute hemorrhagic edema of young children or infantile

immunoglobulin A vasculitis, is habitually a skin-limited small vessel leukocytoclastic vasculitis [1–3]. It characteristically occurs in infants 24 months or less of age, spontaneously remits within 3 weeks and rarely recurs [4].

* Corresponding author. Benedetta Terziroli Beretta-Piccoli - Epatocentro Ticino, Lugano, Switzerland.

E-mail address: benedetta.terziroli@hin.ch (B. Terziroli Beretta-Piccoli).

¹ Equally contributed, co-first authors.

An immune-mediated origin of Finkelstein-Seidlmayer vasculitis has been postulated because it generally follows an acute infection or a vaccination and it has clinical features that resemble immunoglobulin A-mediated vasculitis [5].

This vasculitis is rare and available information is mainly based on individual case reports or small case series. Since the latter have notoriously limitations that hinder a scientific approach to a disease, we initiated the Acute Hemorrhagic Edema Bibliographic Database (AHE-BID), which collects all cases published after the first description more than 100 years ago [4,5]. To better appreciate the possible underlying immune mechanisms, we interrogated this database to evaluate the prevalence of circulating autoimmune markers and vascular immune deposits in these patients.

2. Methods

The Acute Hemorrhagic Edema Bibliographic Database was started by some of us in 2019 [4,5], is being regularly updated and is attainable on request (email: finkelstein-seidlmayer@usi.ch). For this purpose, the bibliography search engines Excerpta Medica, the National Library of Medicine database and Google Scholar are screened every second month for “acute hemorrhagic edema”, “cockade purpura and edema”, “Finkelstein-Seidlmayer” and “infantile Henoch-Schönlein purpura” without any language restriction. We conducted the search in agreement with the revised version of the Preferred Reporting Items for Systematic Reviews and Meta-Analyses. The Acute Hemorrhagic Edema Bibliographic Database also collects secondary references and the literature on Finkelstein-Seidlmayer vasculitis collected by one of us in the 1980s. For all patients, the diagnosis of Finkelstein-Seidlmayer vasculitis made in the original reports was reviewed using three clinical criteria [5]: raised annular or nummular purpuric eruptions and inflammatory skin edema (mostly non-pitting, tender and sometimes also warm) in a well-appearing child.

For the present study, which was pre-registered as PROSPERO CRD42022363996, we extracted published cases of Finkelstein-Seidlmayer vasculitis tested for circulating autoimmune markers (anti-neutrophil cytoplasmic antibodies, antinuclear antibodies, rheumatoid factor, and the subunits of the complement system C4 and C3) or vascular immune deposits (complement subunits, fibrinogen, immunoglobulin A, immunoglobulin E, immunoglobulin G, and immunoglobulin M). The diagnosis of Finkelstein-Seidlmayer vasculitis with systemic involvement was made in cases with abdominal (such as pain, intestinal bleeding, or intussusception), articular (joint pain with or without swelling), or kidney involvement (hematuria with or without associated proteinuria). The disease duration and the occurrence of recurrences, i. e. the reappearance of the disease after a complete recovery for 4 weeks or more were also recorded [2,4]. A preliminary account limited to case published between 1973 and 2018 on vascular immune deposits has been published previously [6].

Categorical variables are shown as counts and were analyzed using the Fisher exact test. Numerical variables are presented as medians and interquartile ranges and were compared using the Mann-Whitney *U* test. Two-sided *P*-values <0.05 were regarded as statistically significant.

3. Results

As of December 1, 2022, the Acute Hemorrhagic Edema Bibliographic Database included (see: supplementary material) 363 original reports (letters, case reports or full-length articles) published in English (N = 193), Spanish (N = 57), French (N = 28), Italian (N = 26), Turkish (N = 25), Portuguese (N = 12), German (N = 11), Dutch (N = 9), Croatian (N = 1), and Danish (N = 1). They have been reported from the following continents: 175 from Europe (Italy, N = 42; Spain, N = 33; France, N = 27; Portugal, N = 16; Germany, N = 12; United Kingdom, N = 11; Netherlands, N = 10; Switzerland, N = 9; Belgium, N = 3; Denmark, N = 3; Croatia, N = 2; Austria, N = 1; Cyprus, N = 1; Greece,

N = 1; Ireland, N = 1; Malta, N = 1; Romania, N = 1; Serbian, N = 1), 111 from Asia (Türkiye, N = 46; India, N = 27; China, N = 7; Israel, N = 7; Iran, N = 7; Japan, N = 4; Saudi Arabia, N = 4; South Korea, N = 2; Lebanon, N = 2; Thailand, N = 2; Jordanian, N = 1; Qatar, N = 1; United Arab Emirates, N = 1), 70 from America (United States, N = 36; Brazil, N = 13; Argentina, N = 9; Mexico, N = 4; Canada, N = 2; Colombia, N = 2; Peru, N = 2; Paraguay, N = 1, Venezuela, N = 1), four from Africa (Morocco, N = 3; South Africa, N = 1), and three from Oceania (Australia, N = 3). The 363 papers (Fig. 1) were published between 1913 and 2022 and addressed 586 individually documented cases (male to female ratio 2.2:1.0, 12 [8–18] months of age). Males (11 [8–18] months of age) and females (12 [8–20] months of age) did not significantly differ with respect to age (*P* = 0.11). The clinical diagnosis of Finkelstein-Seidlmayer vasculitis was supported by a skin biopsy disclosing the distinctive features of a non-granulomatous small vessel leukocytoclastic vasculitis in 269 cases published between 1954 and 2022. Cases with and without the support of a biopsy were similar with respect to sex (male to female ratio 2.2:1.0 versus 2.0:1.0; *P* = 0.37) and age (11 [8–18] versus 12 [9–18] months of age; *P* = 0.23).

A test for at least one circulating autoimmune marker or a vascular immune deposit was performed in 243 cases published between 1973 and 2022: one test in 21, two tests in 72, three tests in 31, four tests in 13, five tests in 14, six tests in 41, seven tests in 11, eight tests in 23, nine tests in 10, 10 tests in five, and 11 tests in two patients. Cases with and without testing for circulating autoimmune markers or vascular immune deposits did not differ with respect to age (11 [8–17] versus 12 [8–18] months of age; *P* = 0.19). The male to female ratio was slightly higher in cases tested for autoimmune markers or immune deposits (2.8:1.0 versus 1.9:1.0; *P* = 0.03). The results of circulating autoimmune markers

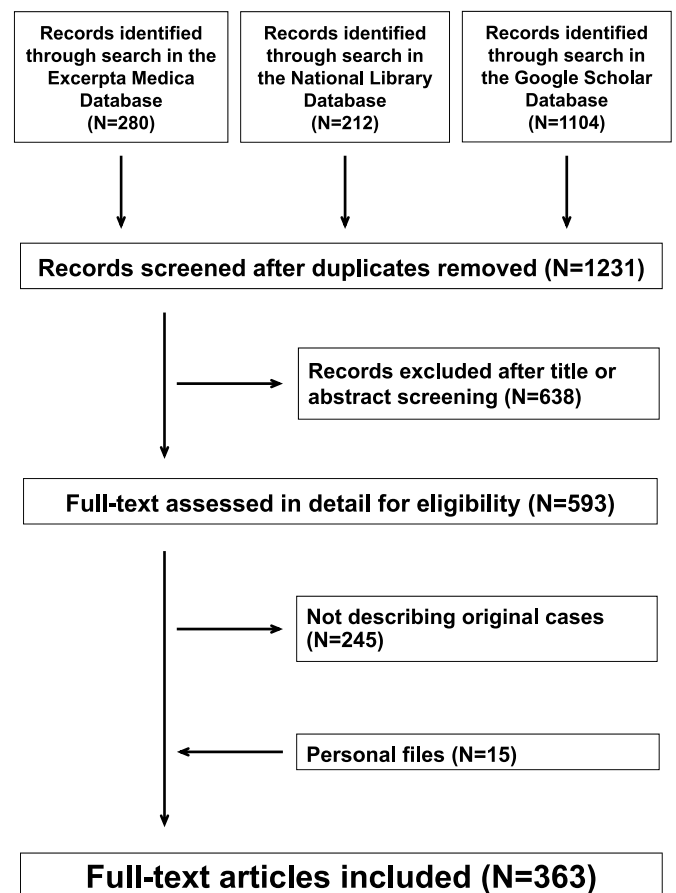


Fig. 1. Finkelstein-Seidlmayer vasculitis. Flowchart of the literature search. The Preferred Reporting Items for Systematic Reviews and Meta-Analyses were followed.

are presented in the upper panel of Fig. 2: the subunits of complement system C4 resulted pathologically reduced in 4.7% and C3 in 1.4% of cases. The rheumatoid factor was detected in 6.1% and antinuclear antibodies in 1.9% of cases. Antineutrophil cytoplasmic antibodies were never demonstrated. An immunofluorescence study was performed on 125 skin biopsy specimens published between 1973 and 2022 and resulted positive for complement subunits in 46%, fibrinogen in 45%, immunoglobulin A in 25%, immunoglobulin M in 24%, immunoglobulin G in 13%, and immunoglobulin E in 4.2% of cases, as shown in the lower panel of Fig. 2.

Infants testing positive and testing negative for vascular immunoglobulin A, immunoglobulin M, immunoglobulin G, immunoglobulin E or complement did not significantly differ with respect to sex ratio, age, prevalence of systemic involvement, disease duration and prevalence of recurrences, as shown in Table 1.

4. Discussion

Routine testing of children with Finkelstein-Seidlmayer vasculitis for autoimmune markers and vascular immunofluorescence deposits is currently not recommended [1–]. Nonetheless, these data are crucial in establishing the underlying pathophysiology. The results of the present

systematic literature review may be recapitulated and discussed as follows.

The low prevalence of antineutrophil cytoplasmic antibodies, antinuclear antibodies, rheumatoid factor, and hypocomplementemia indicates that this condition is a primary vasculitis induced by mechanisms other than those operating in vasculitides that complicate systemic lupus erythematosus or some forms of chronic arthritis [7–9]. They also differ from the mechanisms underlying antineutrophil cytoplasmic antibody associated vasculitides [10] or hypocomplementemic urticarial vasculitis [11].

Following vascular immune deposits were detected, in decreasing order of frequency, in Finkelstein-Seidlmayer vasculitis: complement and fibrinogen in slightly less than every second, immunoglobulin A and immunoglobulin M in every fourth, immunoglobulin G in every tenth and immunoglobulin E in one out of twenty cases. These data support two conclusions. First, the negativity for vascular immunoglobulin A deposits in three quarter of the cases unequivocally distinguishes Finkelstein-Seidlmayer vasculitis from immunoglobulin A vasculitis, a condition associated, by definition, with vascular deposits of IgA1-subclass immunoglobulins, very often associated with mesangial immunoglobulin A deposits [1,2,12]. The different clinical pattern of the two conditions further supports this statement. Finkelstein-Seidlmayer vasculitis is often heralded by a simple infection, predominantly affects infants, is mainly a skin limited condition, and classically presents with targetoid skin lesions and skin edema. In contrast, immunoglobulin A vasculitis usually occurs concomitantly with an infection, characteristically affects children and adolescents, is by definition a systemic disease, and presents with a non-figurate palpable purpura mainly located on buttocks and lower extremities [1,2,12]. Consequently, we discourage the terms infantile Henoch-Schönlein purpura and infantile immunoglobulin A vasculitis, which are sometimes used to denote this condition. Second, the immunofluorescence findings on skin biopsies, although non-specific, resemble those observed in urticarial vasculitis and in systemic lupus erythematosus, and indicate that immune factors play a crucial role in Finkelstein-Seidlmayer vasculitis [12,13].

The mechanisms underlying the development of Finkelstein-Seidlmayer vasculitis remain incompletely understood. Infections might be implicated in many immune-mediated chronic vasculitides [14]. Infections also play a role in immunoglobulin A vasculitis, which tends to develop before resolution of a common infection [1,2]. Similarly, Finkelstein-Seidlmayer vasculitis is temporally associated with an infection (including among others coronavirus disease 2019) or a vaccination in 95% of cases [5]. Most of these cases develop after infection resolution. Finally, some cases (about 10%) are preceded by a vaccination or both a vaccination and an infection [5]. Taken together, these data suggest that common infections play a crucial role also in triggering this vasculitis. Since most infections are not followed by the onset of a vasculitis, a permissive genetic background has been suspected. However, attempts to identify the “genetic smoking gun” explaining infection-associated vasculitides have so far been elusive [15]. In addition to genetic factors, molecular mimicry, microbial persistence, and bystander activation might be implicated in the development of infection-associated vasculitides [16].

The results of this review must be interpreted with an understanding of its inherent limitations, it being based on heterogeneous single case reports and small case series. In particular, original laboratory results were taken as granted. We were not able to verify accuracy of the laboratory technique used for assessing circulating autoimmune markers and vascular immune deposits.

Little is known about the genetic background of Finkelstein-Seidlmayer vasculitis except for a familial cluster with four affected patients [17]. In this family, a report recently released by some of us identified a truncating variant in the HCK gene, which has been associated to some cancers and inflammatory diseases [17].

Vascular immunofluorescence testing is occasionally falsely negative due to skin sampling issues [18]. For example, cutaneous

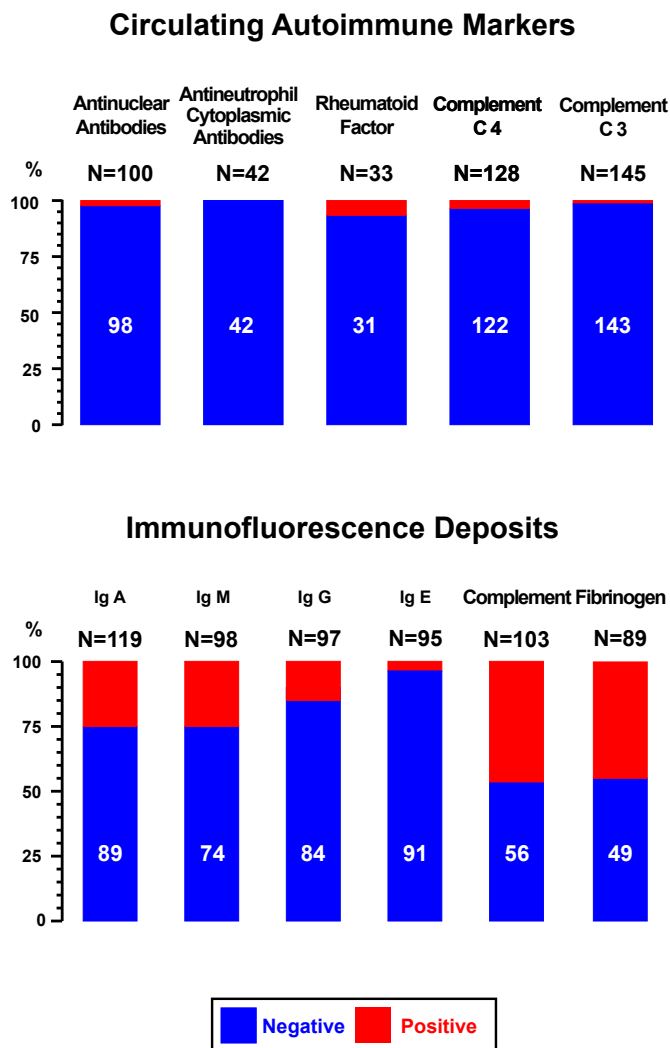


Fig. 2. Circulating autoimmune markers (upper panel) and vascular immune deposits (lower panel) in patients with Finkelstein-Seidlmayer vasculitis. In the upper panel the term positive denotes the presence of antinuclear antibodies, rheumatoid factor or hypocomplementemia.

Table 1

Characteristics of patients tested for vascular immune deposits. Data are presented as counts (and percentage) or as medians (and interquartile ranges). Individual values are given for groups including five or less cases. Sex ratio, age, prevalence of systemic involvement, disease duration, and recurrence rate were not statistically different in cases positive or negative for immunoglobulin A, immunoglobulin M, immunoglobulin G, immunoglobulin E or complement.

	Immunoglobulin A		Immunoglobulin M		Immunoglobulin G		Immunoglobulin E		Complement	
	Negative	Positive	Negative	Positive	Negative	Positive	Negative	Positive	Negative	Positive
N	89	30	74	24	84	13	91	4	56	47
Males: females, N	66:23	24:6	55:19	20:4	66:18	9:4	72:19	3:1	45:11	33:14
Age, months	12 [7–14]	11 [7–16]	11 [7–21]	10 [6–14]	11 [8–16]	8 [5–12]	10 [8–16]	6; 12; 12; 13	11 [8–18]	10 [7–14]
Systemic involvement, N (%)	11 (12)	5 (16)	11 (15)	3 (12)	13 (15)	1 (7.7)	14 (15)	0 (0)	6 (11)	6 (13)
Disease duration, days	10 [7–14]	13 [7–20]	12 [10–21]	8 [6–14]	10 [7–14]	7 [6–13]	10 [7–14]	5; 9; 11 ^a	10 [7–15]	10 [7–13]
Recurrences, N (%)	6 (6.7)	2 (6.7)	3 (4.1)	1 (4.2)	4 (4.7)	1 (7.7)	6 (6.6)	0 (0)	5 (8.9)	1 (2.1)

^a Information not available in one patient.

immunoglobulin A deposits are not detected in about 10% of patients affected by immunoglobulin A vasculitis [18]. To minimize false-negative results, it is recommended that biopsy should be taken from the edge of fresh lesions [18]. However, it is hardly conceivable that an inappropriate skin sample collection may explain the negativity for immunoglobulin A testing in 75% of cases included in this review.

5. Conclusions

These data suggest that there is a very low prevalence of autoimmune marker positivity in Finkelstein-Seidlmayer vasculitis. Furthermore, Finkelstein-Seidlmayer and immunoglobulin A vasculitis differ not only clinically but also pathophysiologically. Finally, available immunofluorescence data support the notion that immune factors play a relevant role in this vasculitis. More than 100 years after the first description, Finkelstein-Seidlmayer vasculitis appears more and more to be a distinctive condition. The time has come to include it in the classification of skin vasculitides [19].

Appendix A. Supplementary data

Supplementary data to this article can be found online at <https://doi.org/10.1016/j.jaut.2023.103002>.

References

- [1] T.V. Ting, Diagnosis and management of cutaneous vasculitis in children, *Pediatr. Clin.* 61 (2) (2014) 321–346, <https://doi.org/10.1016/j.pcl.2013.11.007>.
- [2] S.A.G. Lava, G.P. Milani, E.F. Fossali, G.D. Simonetti, C. Agostoni, M.G. Bianchetti, Cutaneous manifestations of small-vessel leukocytoclastic vasculitides in childhood, *Clin. Rev. Allergy Immunol.* 53 (3) (2017) 439–451, <https://doi.org/10.1007/s12016-017-8626-3>.
- [3] A.K.C. Leung, K.F. Leong, J.M. Lam, Acute hemorrhagic edema of infancy: a diagnostic challenge for the general pediatrician, *Curr. Pediatr. Rev.* 16 (4) (2020) 285–293, <https://doi.org/10.2174/1573396316666200727145039>.
- [4] P.O. Rinoldi, G. Bronz, A. Ferrarini, C. Mangas, M.G. Bianchetti, C. Chelleri, S.A. G. Lava, G.P. Milani, Acute hemorrhagic edema: uncommon features, *J. Am. Acad. Dermatol.* 85 (6) (2021) 1620–1621, <https://doi.org/10.1016/j.jaad.2020.12.033>.
- [5] G. Bronz, C. Betti, P.O. Rinoldi, L. Kottanattu, M.G. Bianchetti, D. Consolascio, M. M. Bergmann, G.P. Milani, B. Terziroli Beretta Piccoli, S.A.G. Lava, Infections or vaccines associated with Finkelstein-Seidlmayer vasculitis: systematic review, *Clin. Rev. Allergy Immunol.* 63 (3) (2022) 490–498, <https://doi.org/10.1007/s12016-022-08940-2>.
- [6] G. Pellanda, S.A.G. Lava, G.P. Milani, M.G. Bianchetti, A. Ferrarini, F. Vanoni, Immune deposits in skin vessels of patients with acute hemorrhagic edema of young children: a systematic literature review, *Pediatr. Dermatol.* 37 (1) (2020) 120–123, <https://doi.org/10.1111/pde.14041>.
- [7] K. Chakravarty, V.H. Ong, C.P. Denton, Secondary vasculitis in autoimmune connective tissue diseases, *Curr. Opin. Rheumatol.* 28 (1) (2016) 60–65, <https://doi.org/10.1097/BOR.0000000000000241>.
- [8] E. Calle-Botero, A. Abril, Lupus vasculitis, *Curr. Rheumatol. Rep.* 22 (10) (2020) 71, <https://doi.org/10.1007/s11926-020-00937-0>.
- [9] J. Keightley, J. Walsh, R.M. Bland, How to use autoantibodies in suspected paediatric rheumatic disease, *Arch Dis Child Educ Pract Ed* 107 (4) (2022) 236–241, <https://doi.org/10.1136/archdischild-2021-323212>.
- [10] S. Almaani, L.A. Fussner, S. Brodsky, A.S. Meara, D. Jayne, ANCA-associated vasculitis: an update, *J. Clin. Med.* 10 (7) (2021) 1446, <https://doi.org/10.3390/jcm10071446>.
- [11] M.D. Davis, J.D. Brewer, Urticarial vasculitis and hypocomplementemic urticarial vasculitis syndrome, *Immunol. Allergy Clin.* 24 (2) (2004) 183–213, <https://doi.org/10.1016/j.iac.2004.01.007>.
- [12] M.H. Heineke, A.V. Ballering, A. Jamin, S. Ben Mkaddem, R.C. Monteiro, M. Van Egmond, New insights in the pathogenesis of immunoglobulin A vasculitis (Henoch-Schönlein purpura), *Autoimmun. Rev.* 16 (12) (2017) 1246–1253, <https://doi.org/10.1016/j.autrev.2017.10.009>.
- [13] J.E. Weiss, Pediatric systemic lupus erythematosus: more than a positive antinuclear antibody, *Pediatr. Rev.* 33 (2) (2012) 62–74, <https://doi.org/10.1542/pir.33-2-62>.
- [14] M.M. van Timmeren, P. Heeringa, C.G. Kallenberg, Infectious triggers for vasculitis, *Curr. Opin. Rheumatol.* 26 (4) (2014) 416–423, <https://doi.org/10.1097/BOR.0000000000000068>.
- [15] I.R. Mackay, M.E. Gershwin, The nature of autoimmune disease, *Semin. Liver Dis.* 17 (1) (1997) 3–11, <https://doi.org/10.1055/s-2007-1007178>.
- [16] R. Root-Bernstein, D. Fairweather, Complexities in the relationship between infection and autoimmunity, *Curr. Allergy Asthma Rep.* 14 (1) (2014) 407, <https://doi.org/10.1007/s11882-013-0407-3>.
- [17] G. Bronz, H. Gabriel, S.A.G. Lava, G.P. Ramelli, M. Luedeke, S. Biskup, C. Mainetti, A. Ferrarini, Whole exome sequencing revealed a candidate gene for Finkelstein-Seidlmayer disease, *Am J Pediatr* 5 (4) (2019) 196–199, <https://doi.org/10.11648/j.ajp.20190504.15>.
- [18] J.C. Davin, J.J. Weening, Diagnosis of Henoch-Schönlein purpura: renal or skin biopsy? *Pediatr. Nephrol.* 18 (12) (2003) 1201–1203, <https://doi.org/10.1007/s00467-003-1292-0>.
- [19] M. Caproni, A. Verdelli, An update on the nomenclature for cutaneous vasculitis, *Curr. Opin. Rheumatol.* 31 (1) (2019) 46–52, <https://doi.org/10.1097/BOR.0000000000000563>.